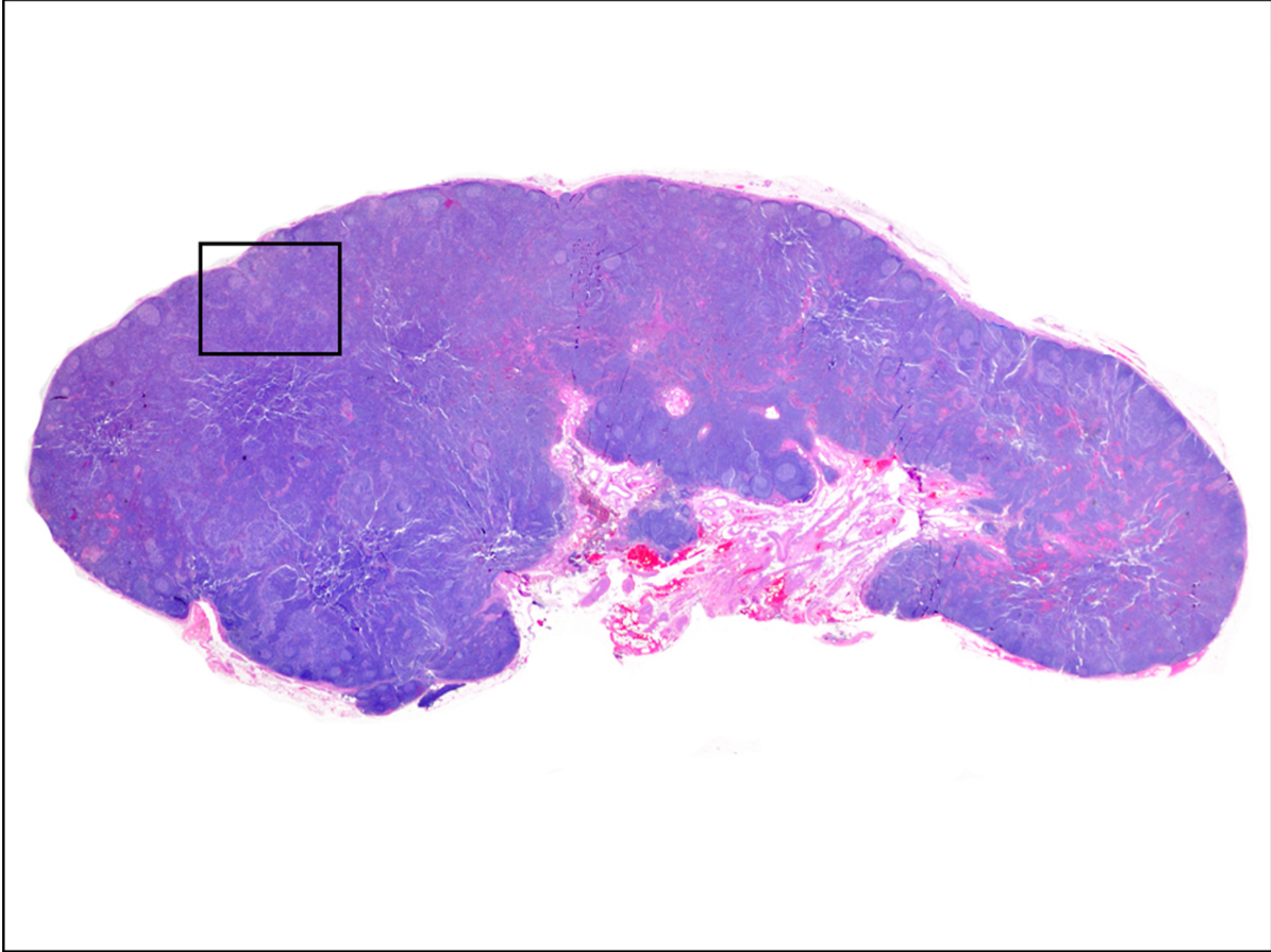
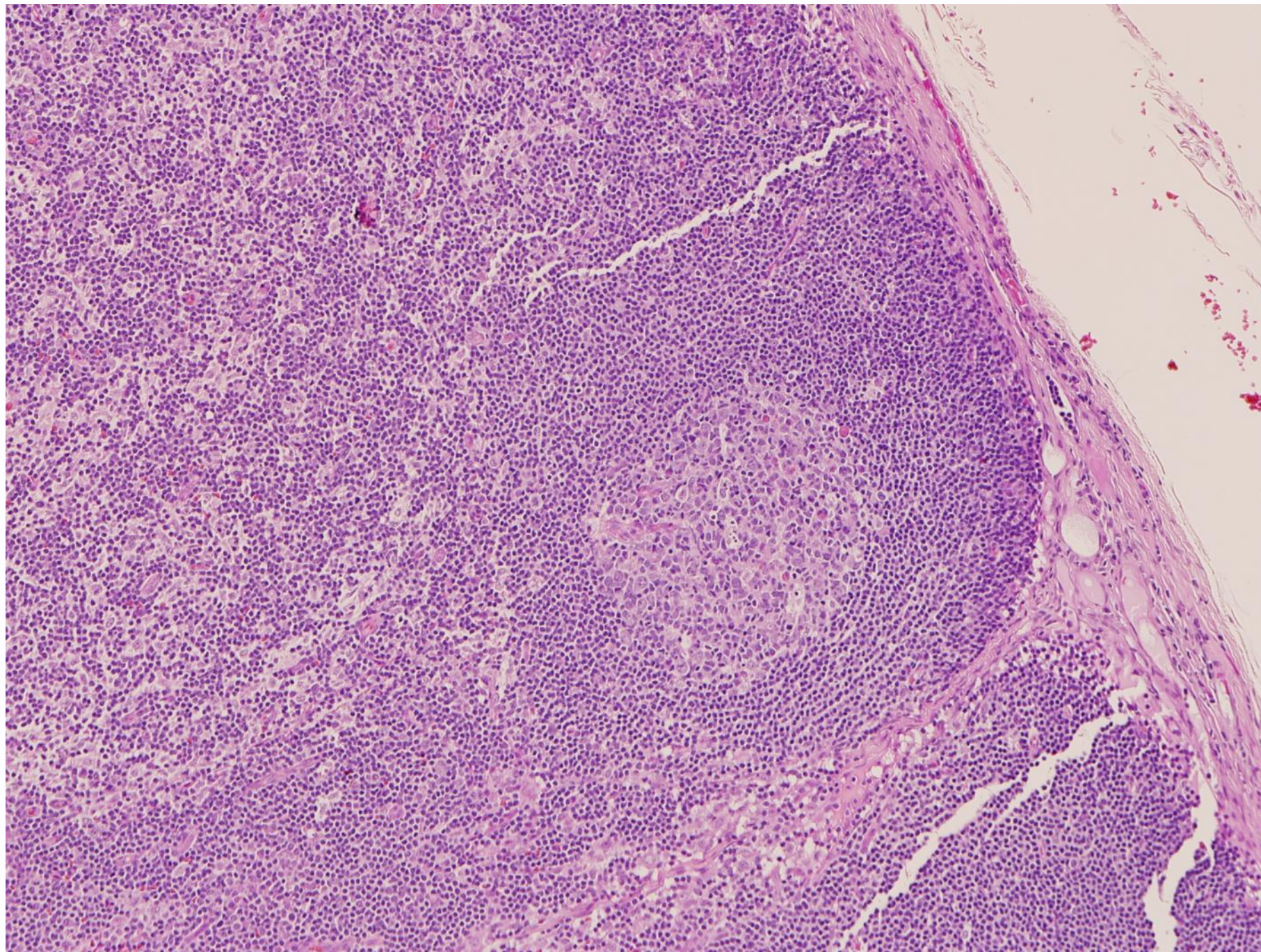


## Case 3

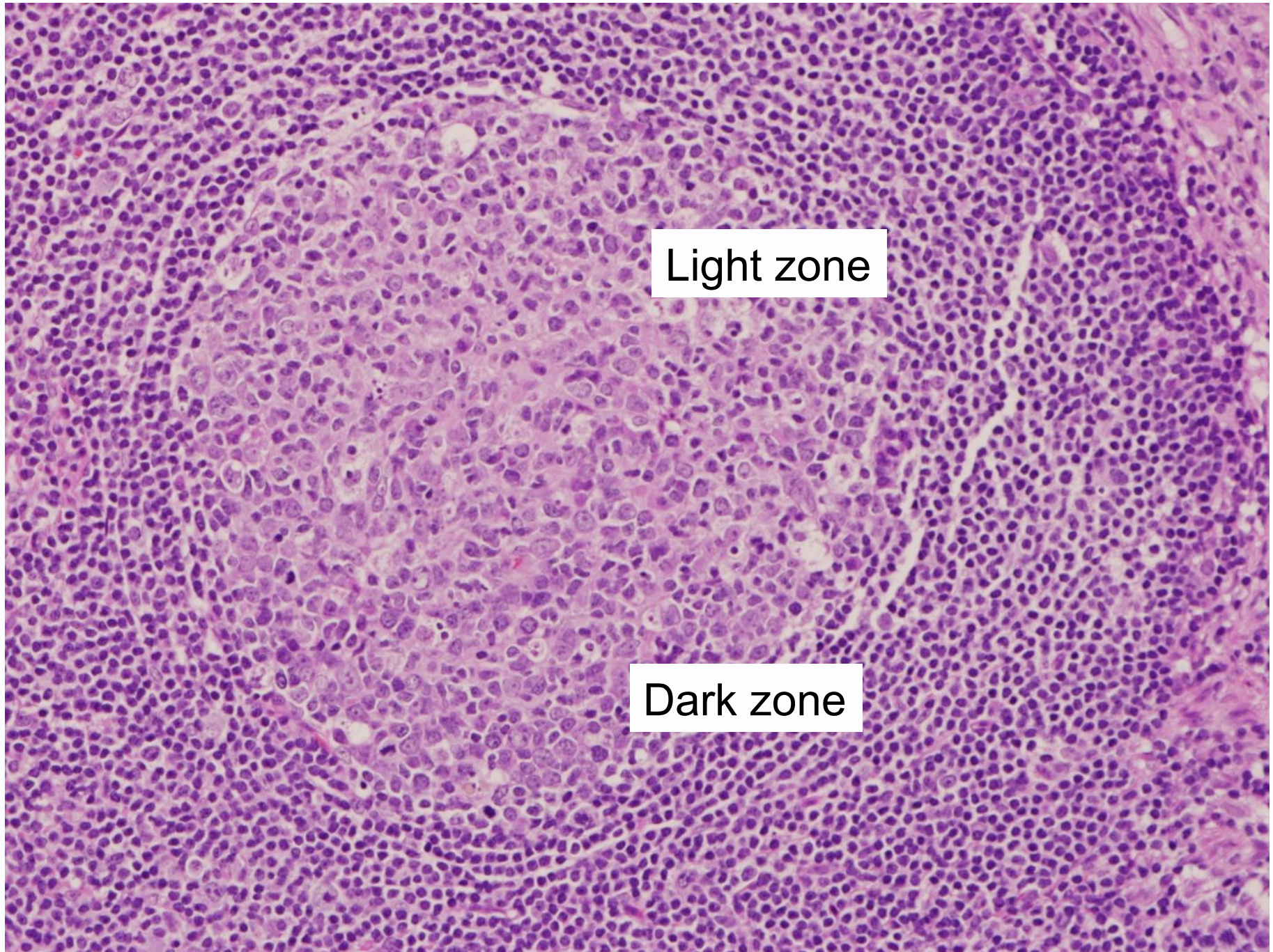
- A 63 year old female was found to have an enlarged cervical lymph node during carotid endarterectomy. Further clinical evaluation showed no evidence of lymphoma. Bone marrow examination was negative.









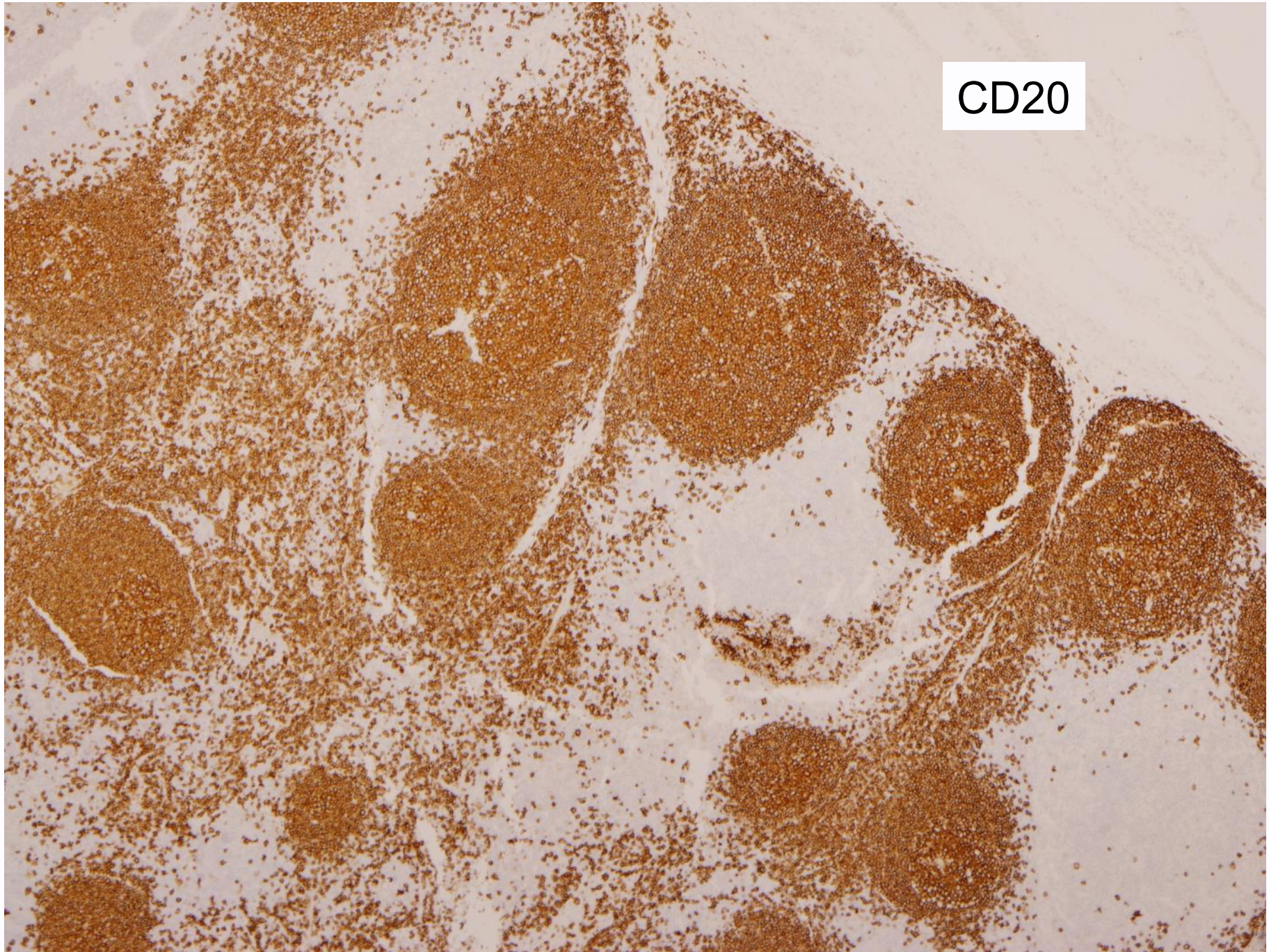


Light zone

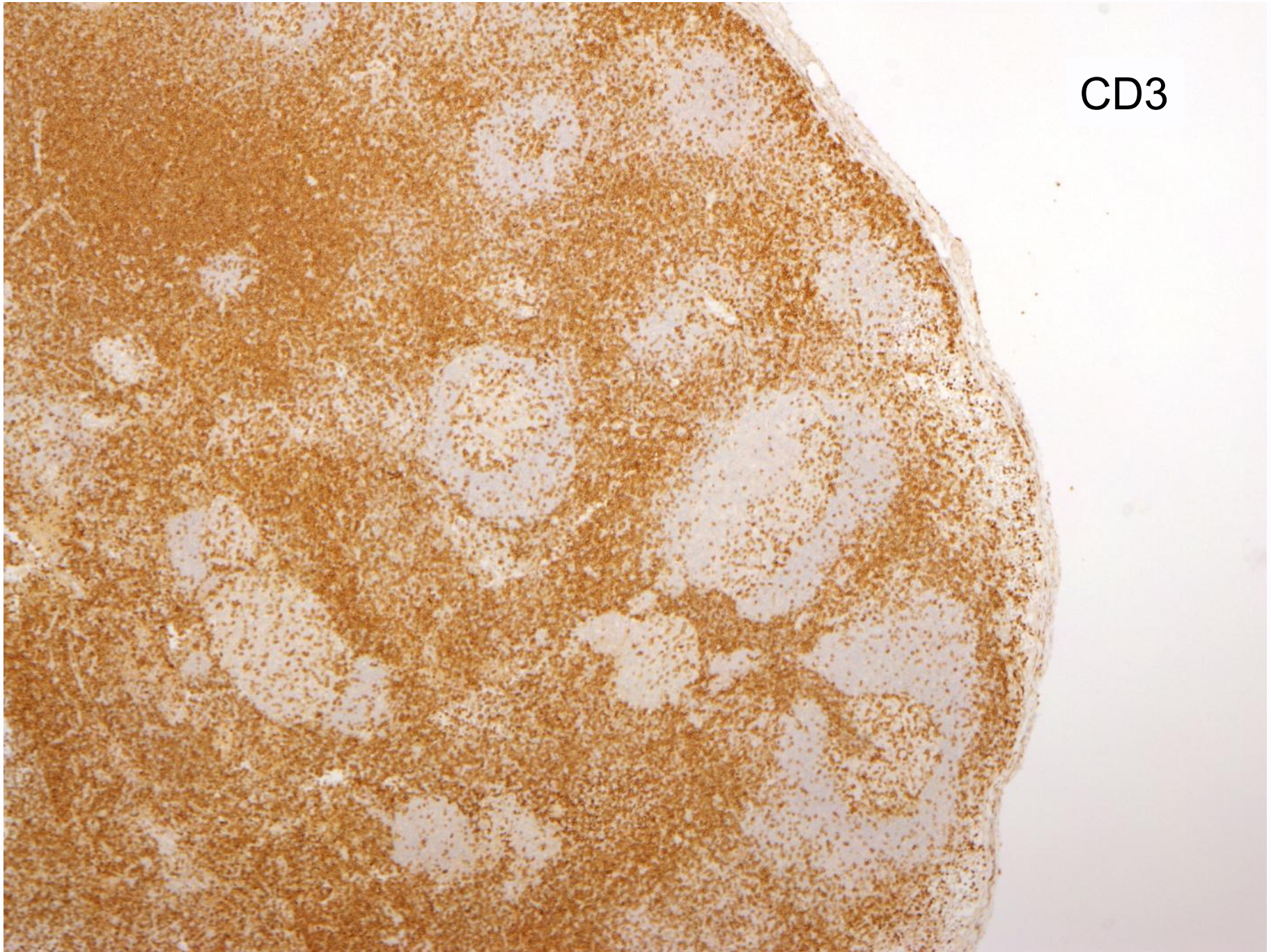
Dark zone



CD20

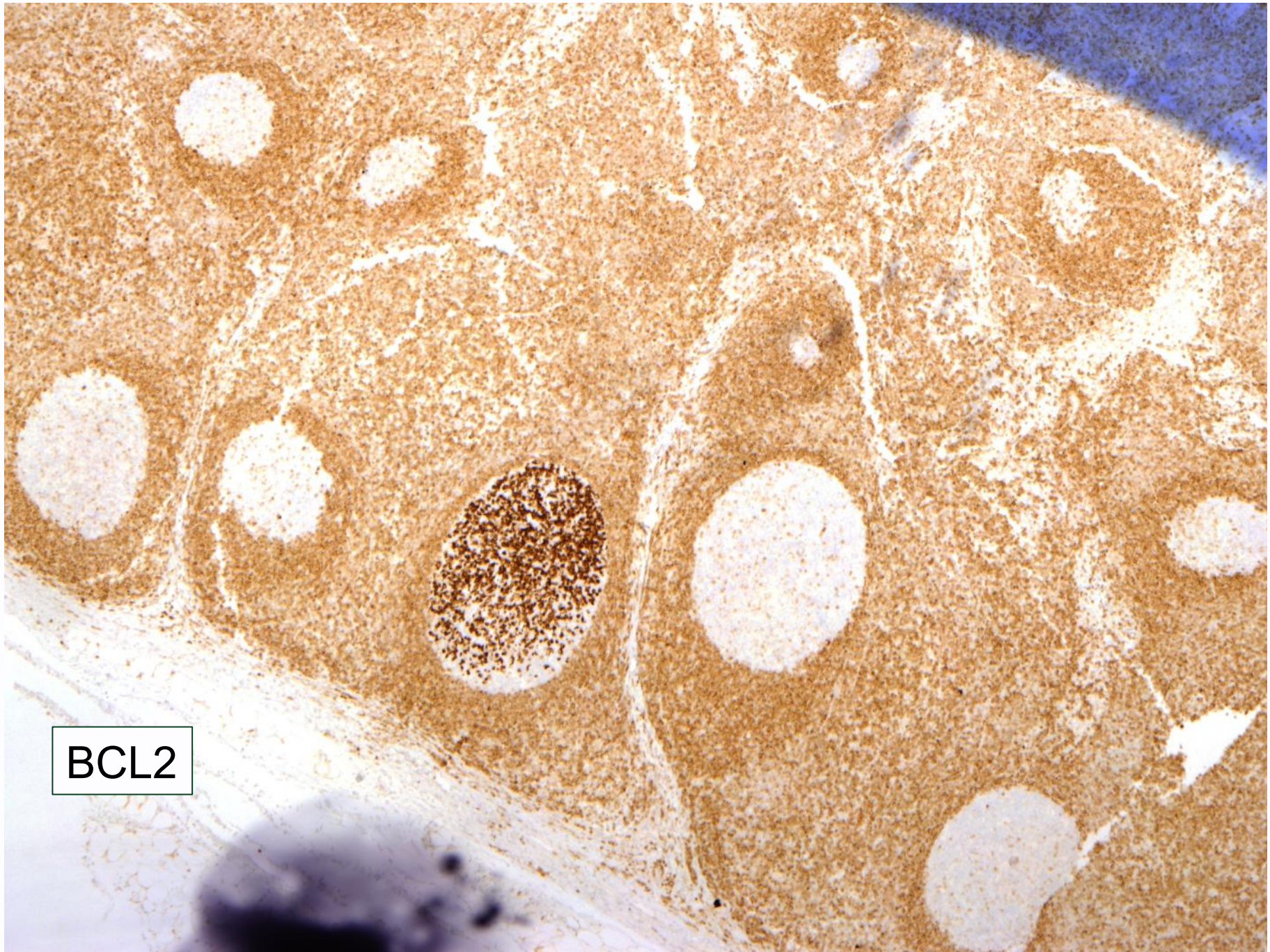






CD3

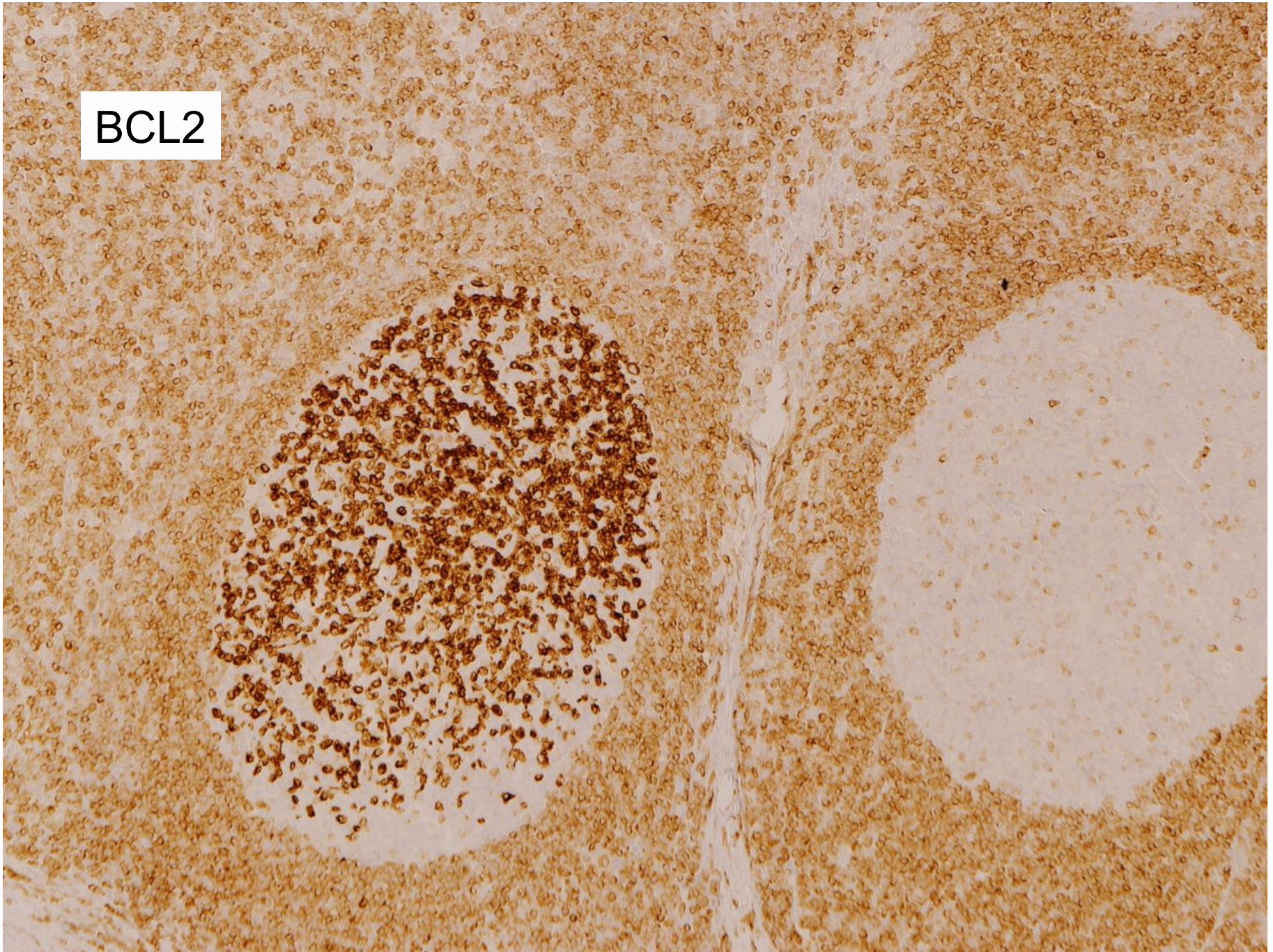




BCL2

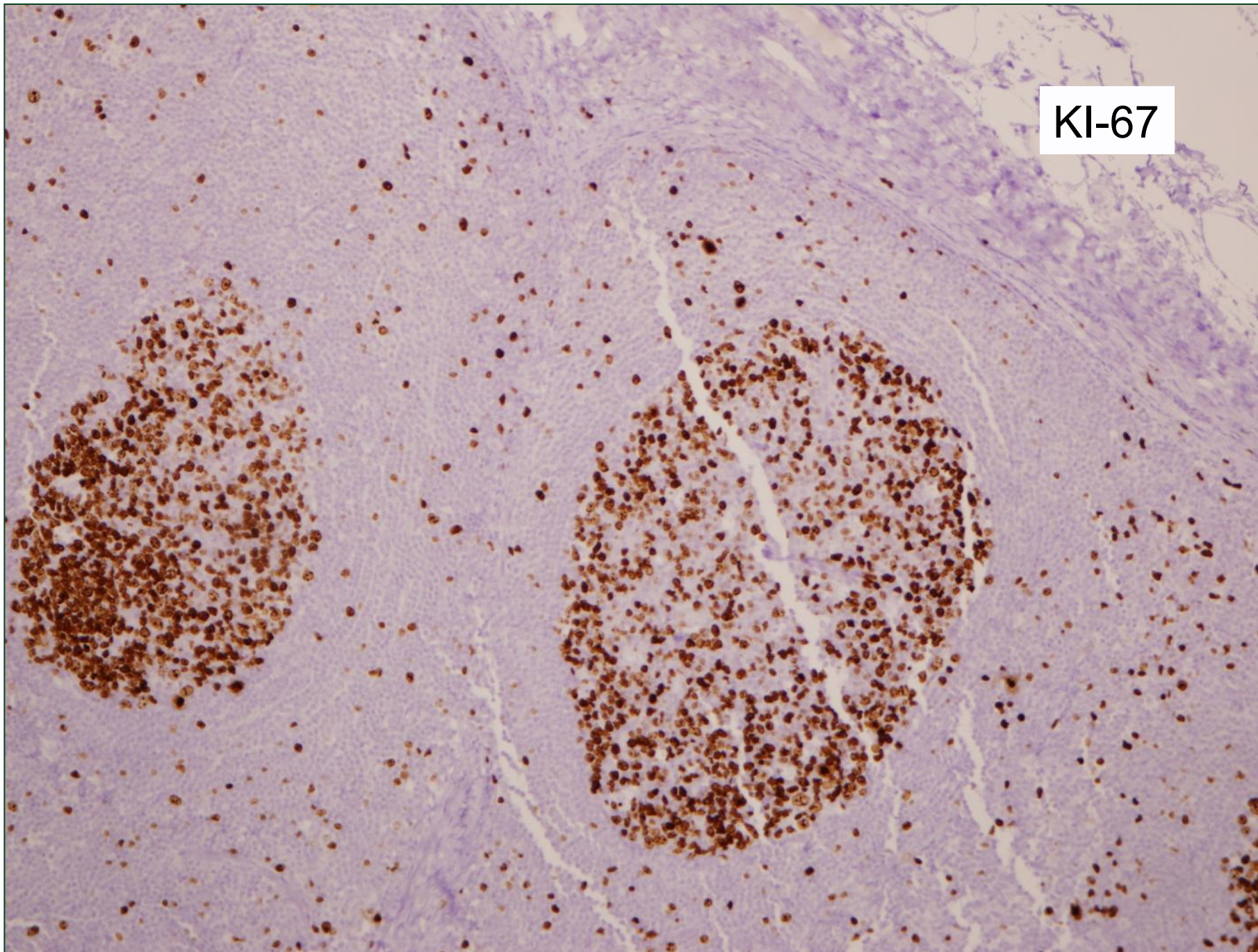


BCL2

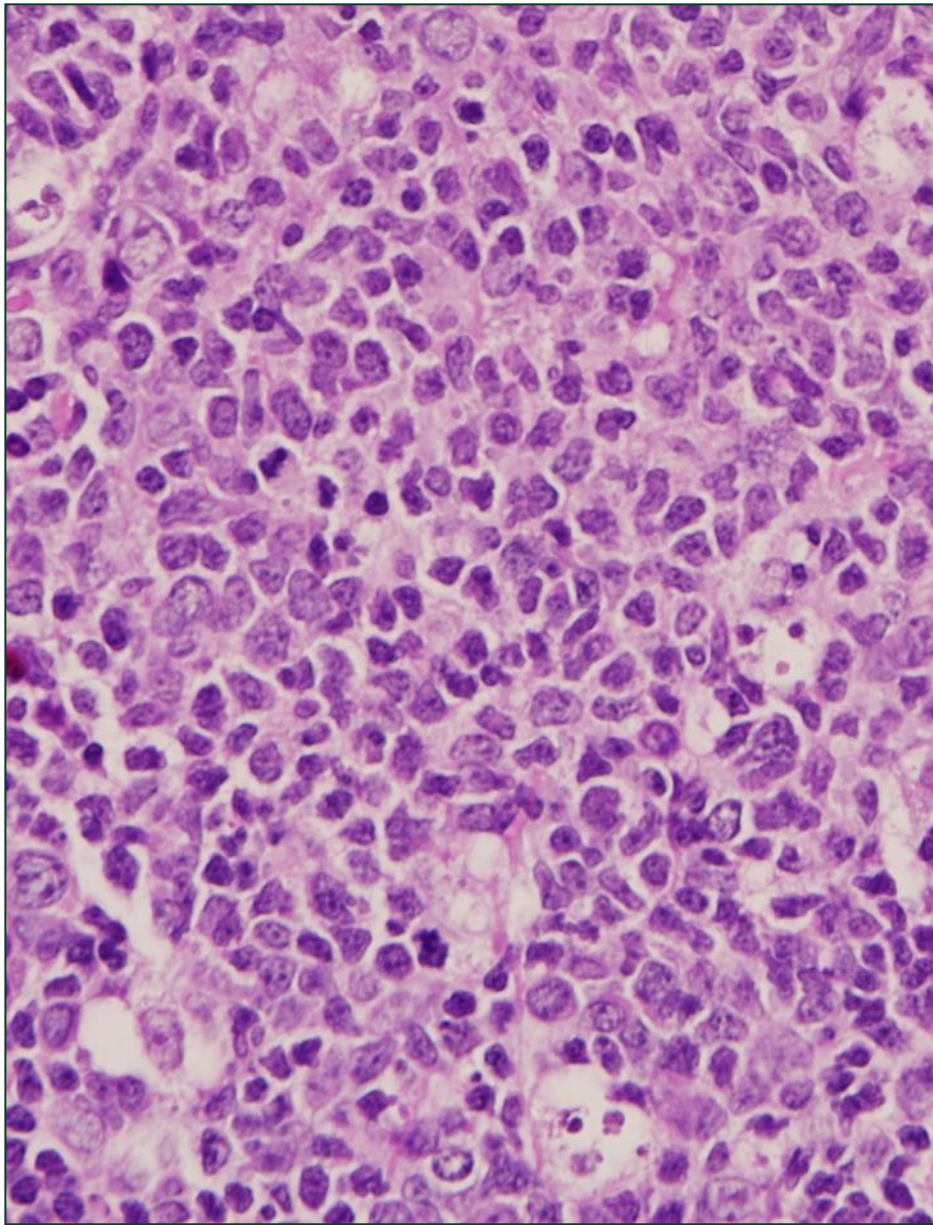




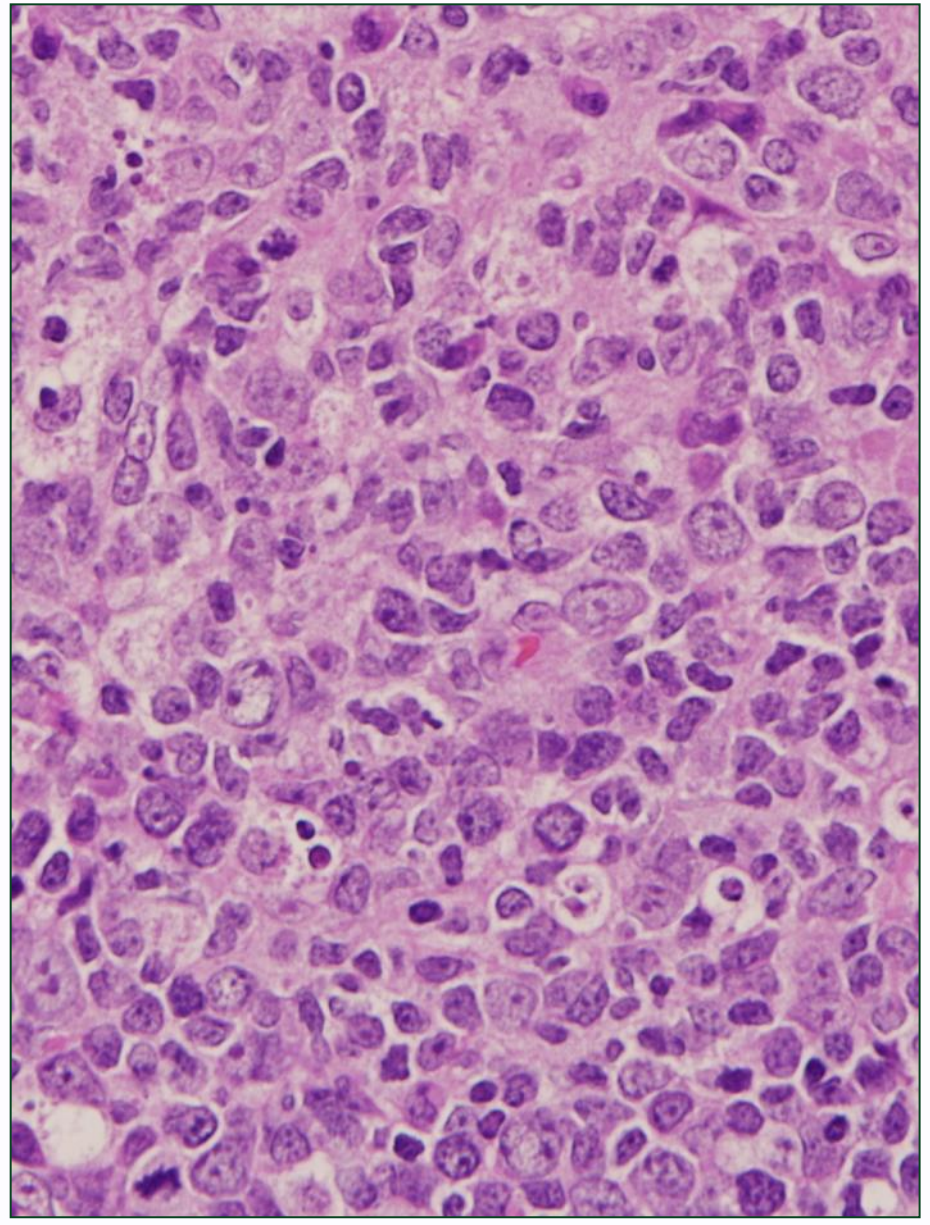
KI-67







FLIS



Reactive GC



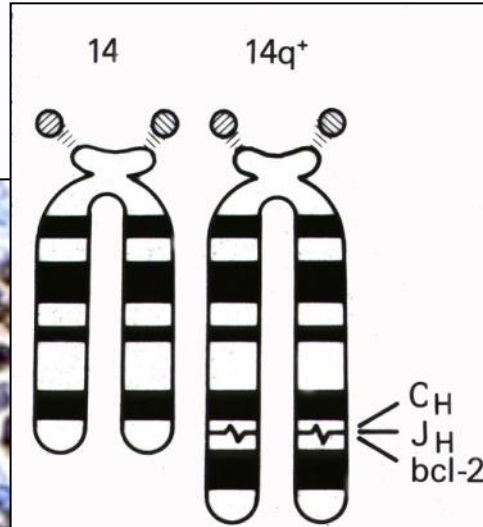
## Case 3

Diagnosis:

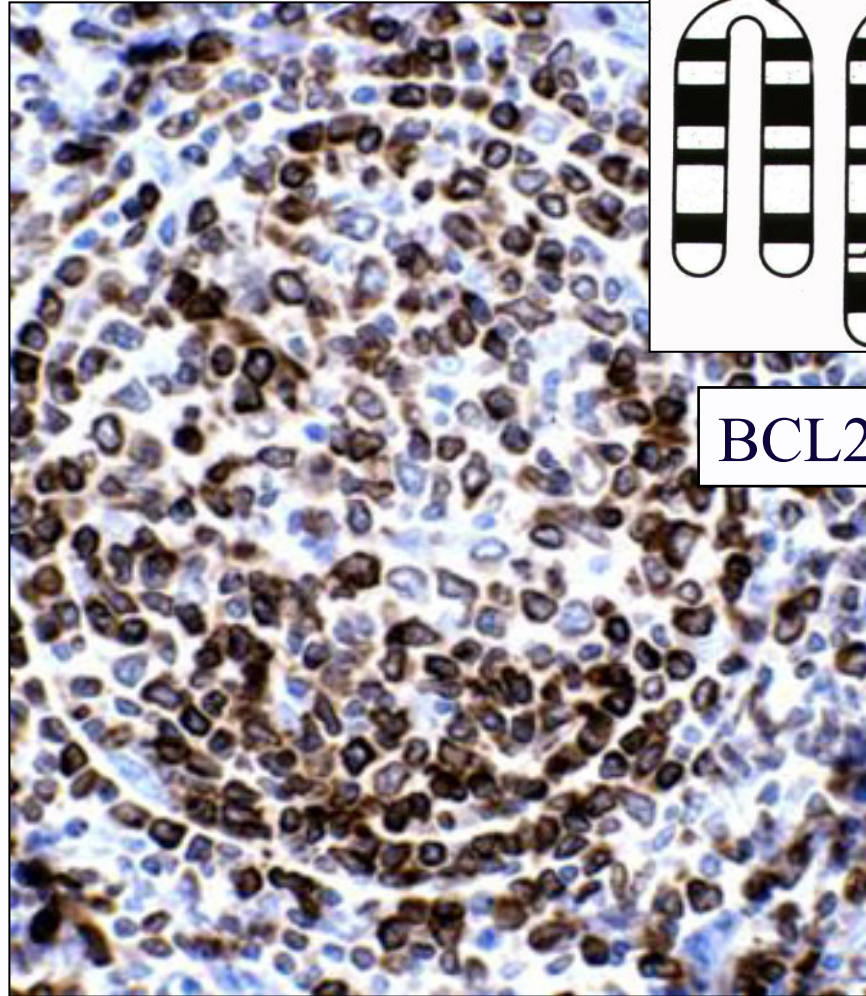
Follicular lymphoma, In situ  
(FL-like B-cells of undetermined significance)



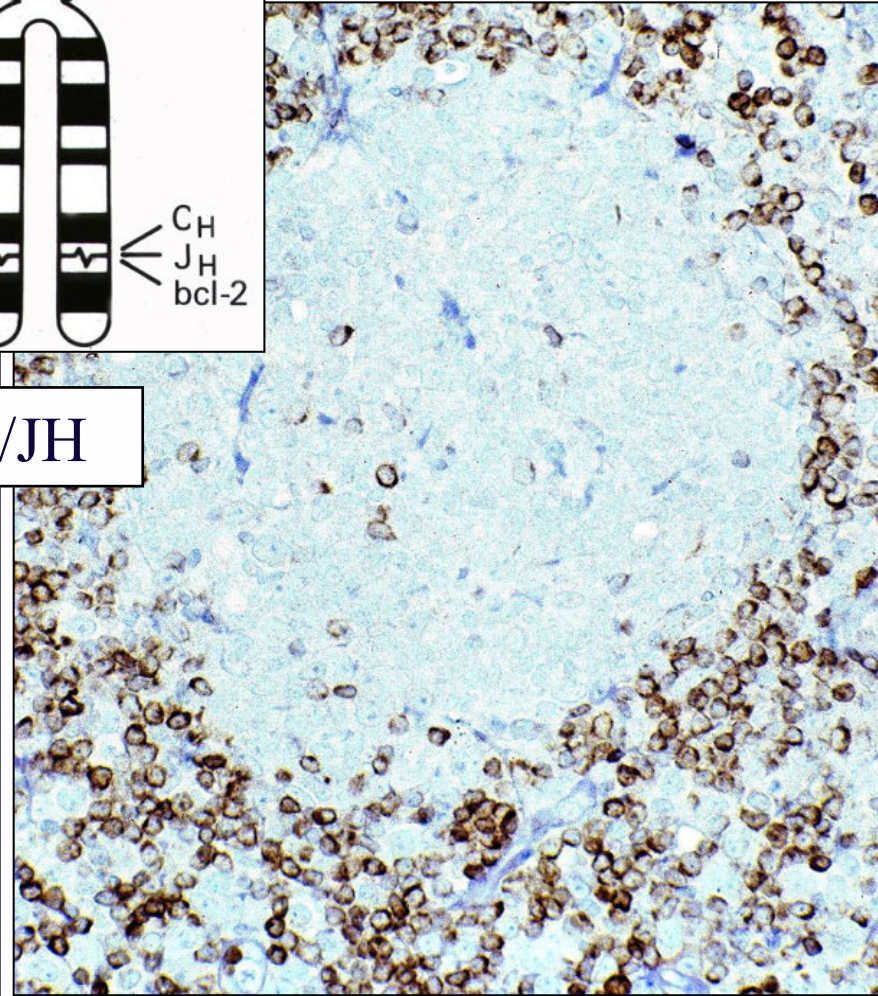
Tsujimoto, Croce  
Science 1985



Gaulard, Mason  
AJP 1992



Follicular lymphoma

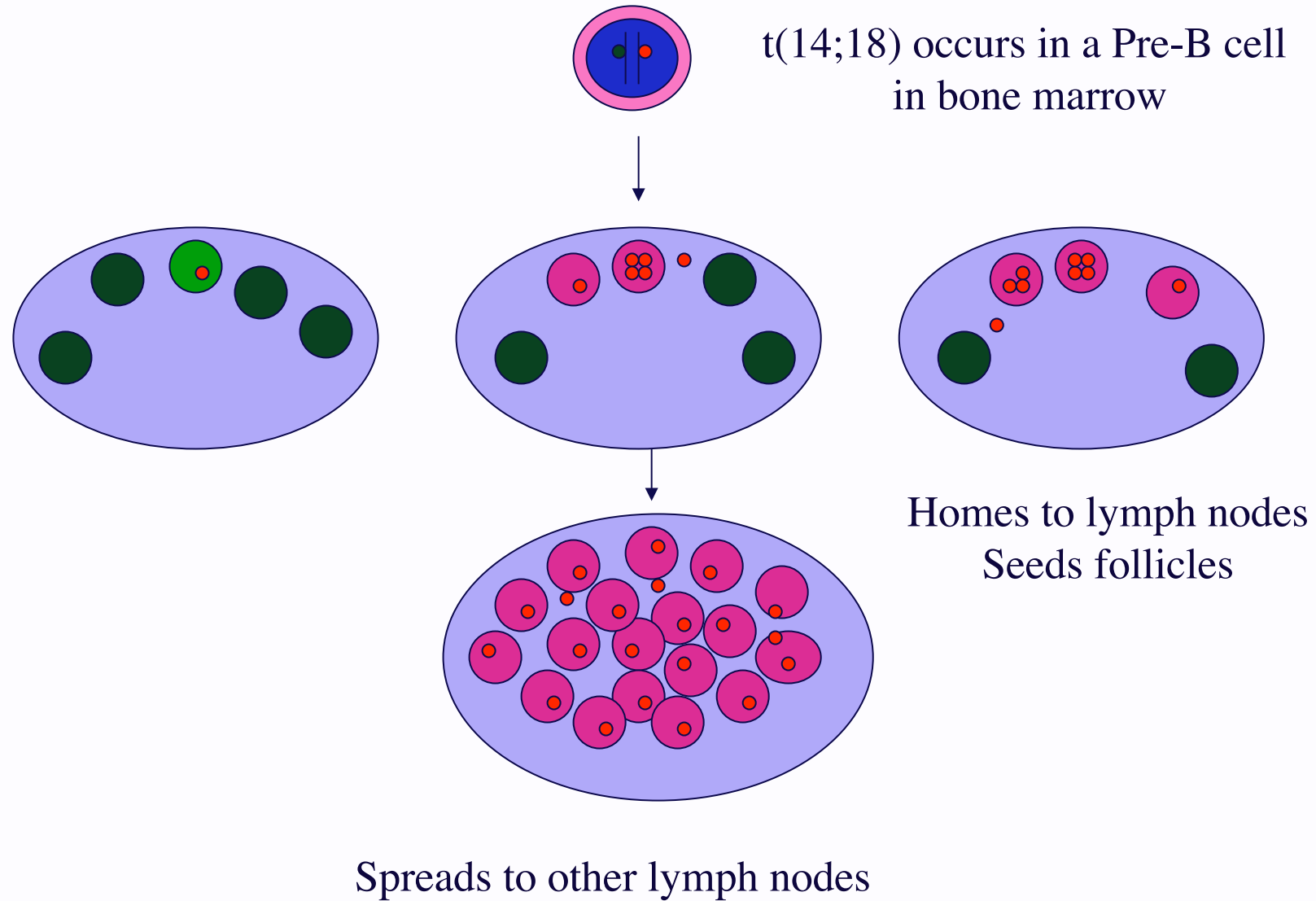


Germinal Center

BCL2/JH



# Follicular Lymphomagenesis

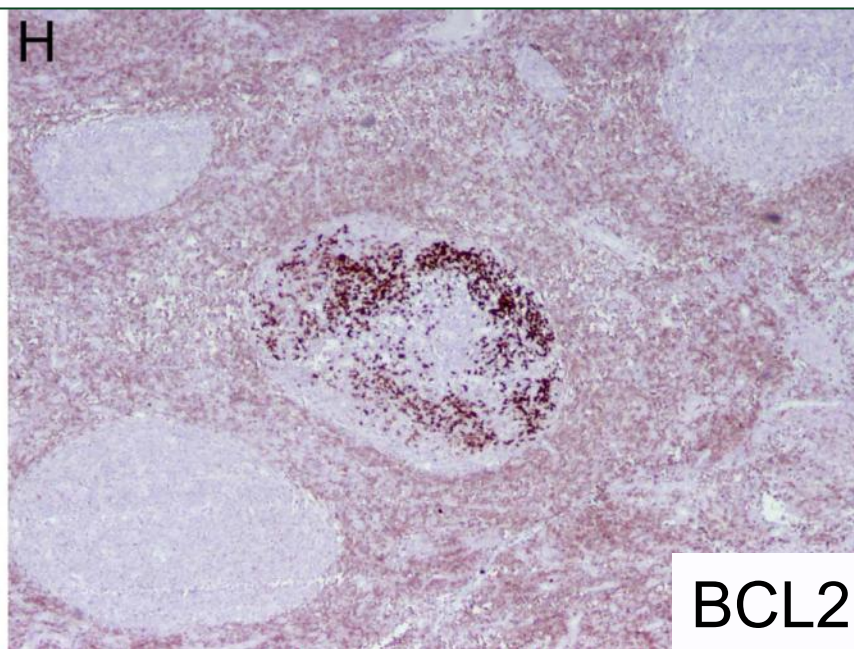
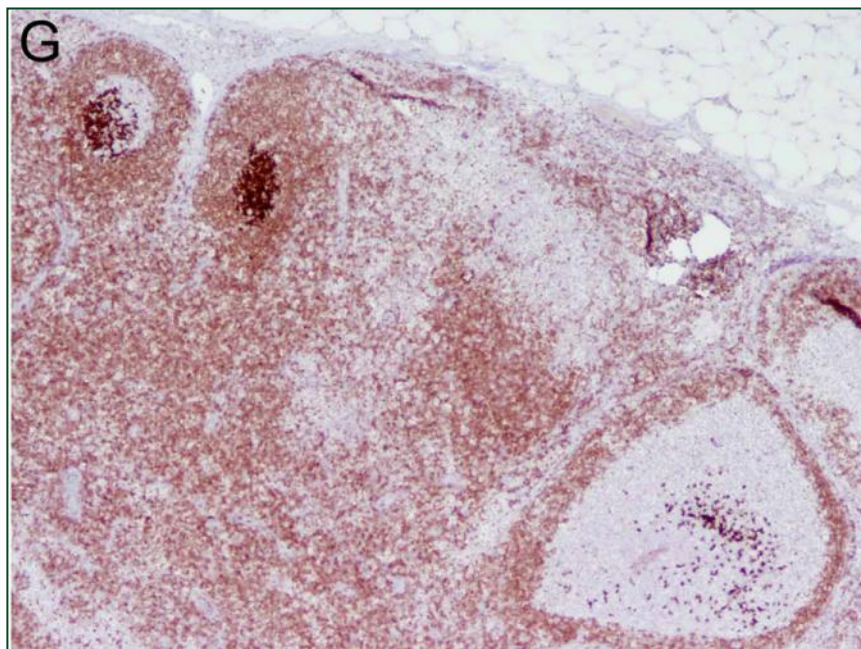
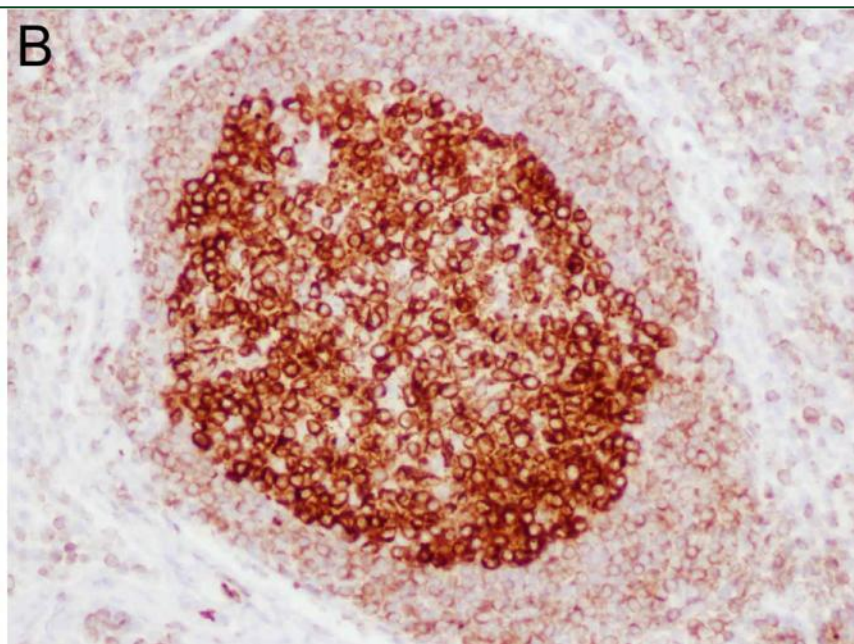
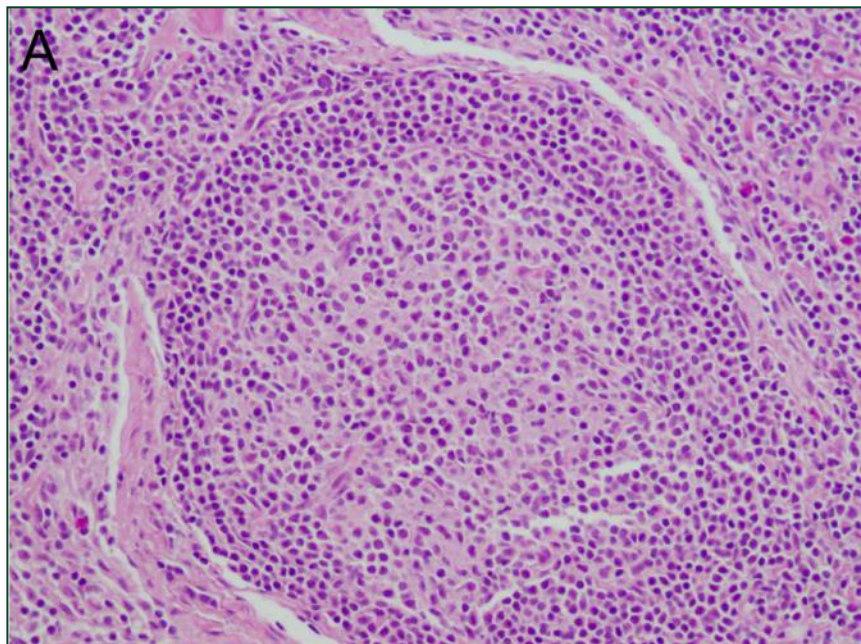




## “In Situ” Follicular lymphoma

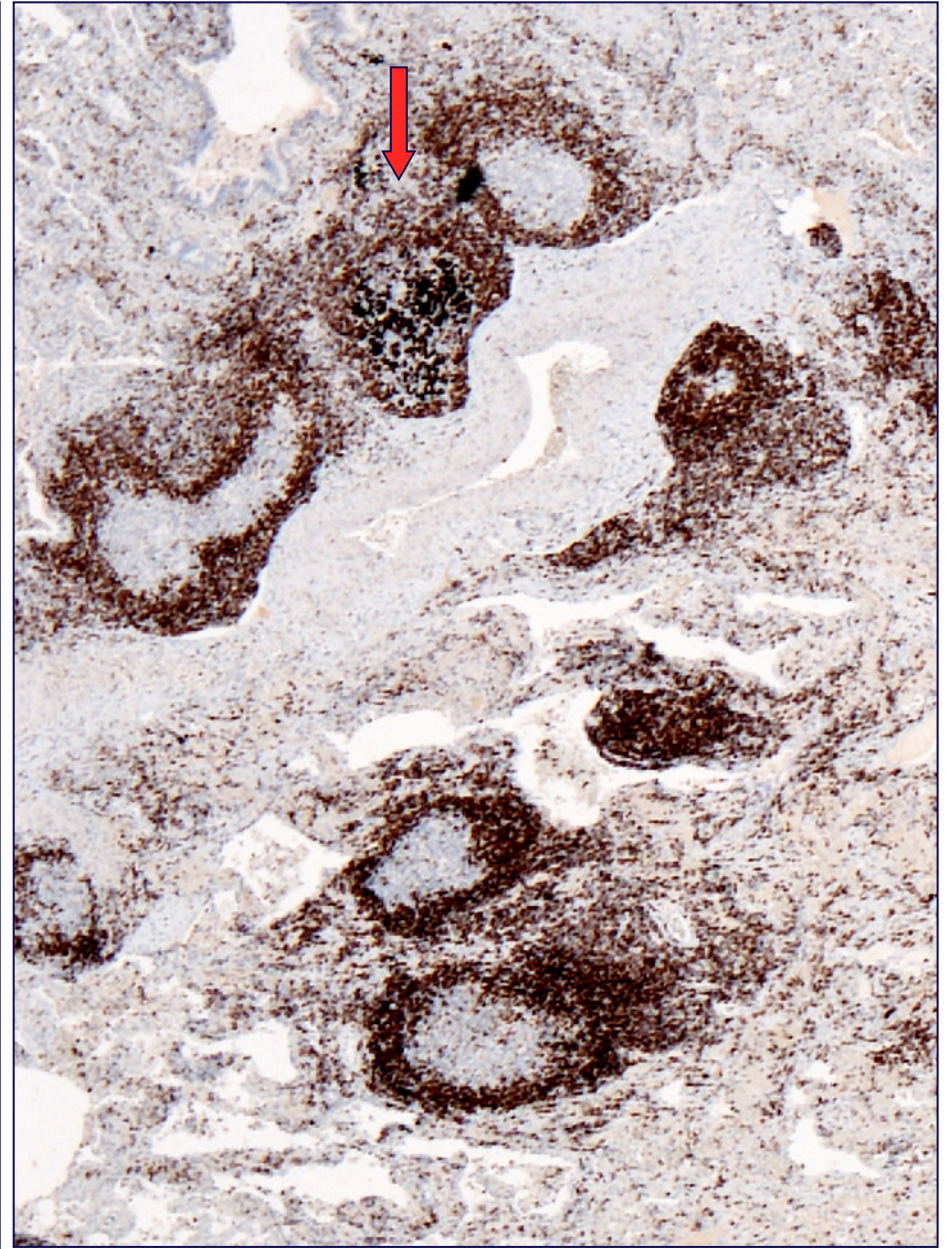
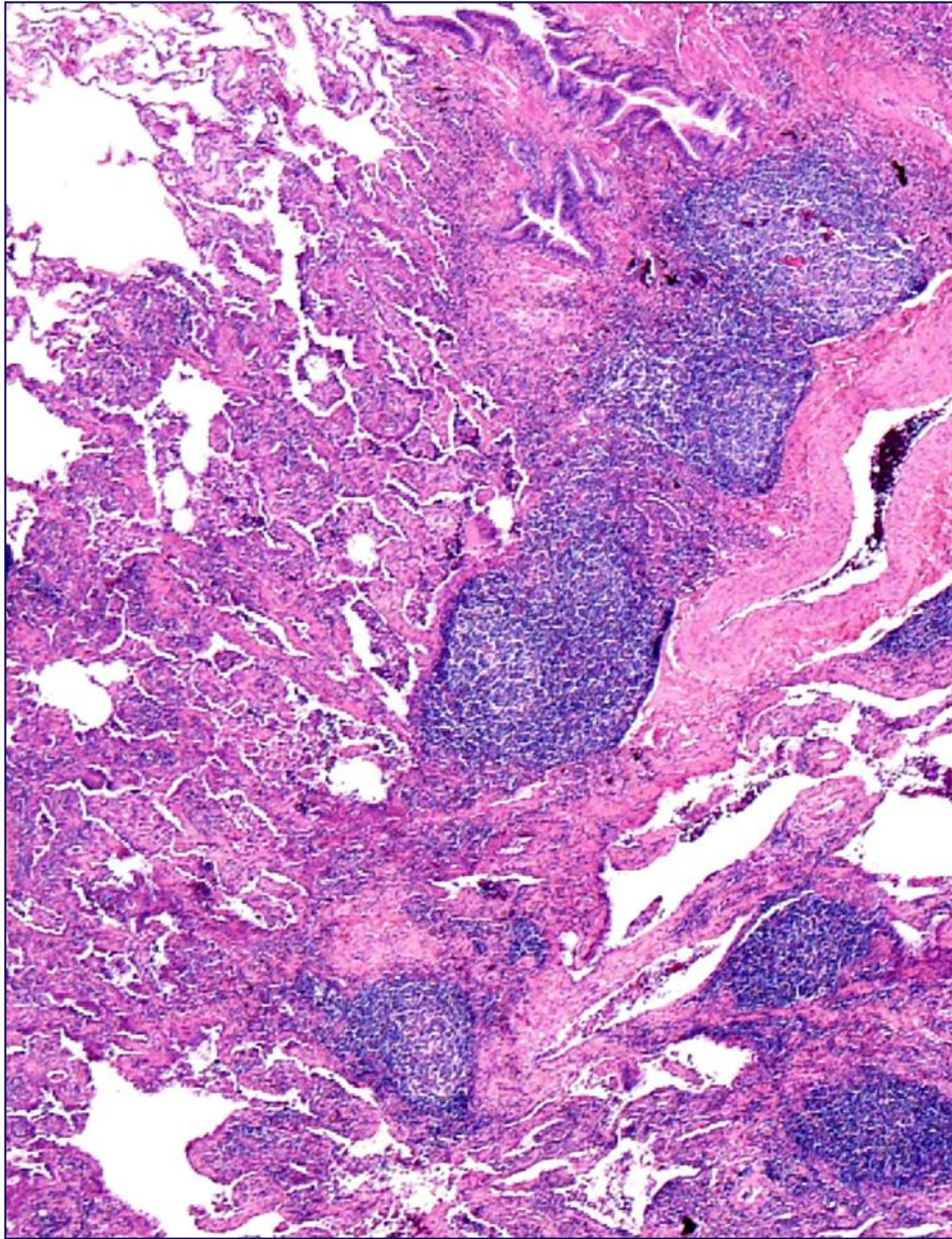
- 23 Cases, Median age 52.5
  - original series (Cong, 2002)
- Incidence estimated at <5% of all reactive LN biopsies
- 2 cases were incidentally associated with other B-cell lymphomas
  - CLL & LPL





BCL2





FL in situ in lung resection for adenoca